


12

AUTOPSY REPORT ADULT FORM PROTOCOL

No.



Bennington, Chester

I performed an autopsy on the body of 
at the DEPARTMENT OF MEDICAL EXAMINER-CORONER

Los Angeles, California on 7-21-17 1040
(Date) (Time)

From the anatomic findings and pertinent history I ascribe the death to:

(A) Hanging
DUE TO OR AS A CONSEQUENCE OF

(B)
DUE TO OR AS A CONSEQUENCE OF

(C)
DUE TO OR AS A CONSEQUENCE OF

(D)
OTHER CONDITIONS CONTRIBUTING BUT NOT RELATED TO THE IMMEDIATE CAUSE OF DEATH

Anatomical Summary:

<input type="checkbox"/> As listed below <input type="checkbox"/> See form #16 under gross impressions

1. Hanging
 - A) Belt ligature on neck
 - B) Rare conjunctival petechiae
 - C) Ligature mark on neck
 - D) Hemorrhage of left sternomastoid muscle
2. History of suicidal ideation

CC#



Bemington, Chester
name

IF A TRAUMA CASE STATE:

Injury date: 7-20-17 Hospital Date(s): _____

CIRCUMSTANCES:

<input checked="" type="checkbox"/> See Investigator Report form #3 <input type="checkbox"/> As listed below <input type="checkbox"/> Source: _____

EXTERNAL EXAMINATION:

The body is identified by toe tags and is that of an unembalmed/embalmed refrigerated,

<input checked="" type="checkbox"/> adult <input type="checkbox"/> elderly <input type="checkbox"/> teenage	<input type="checkbox"/> female <input checked="" type="checkbox"/> male	<input type="checkbox"/> Asian <input type="checkbox"/> Black <input checked="" type="checkbox"/> Caucasian <input type="checkbox"/> Hispanic
---	---	--

who appears

<input checked="" type="checkbox"/> about the reported <input type="checkbox"/> older than the reported <input type="checkbox"/> the reported <input type="checkbox"/> younger than the reported

age of 41 years.

The body weighs 167 pounds,
measures 69 inches and is

<input type="checkbox"/> cachectic. <input type="checkbox"/> mildly/moderately/extremely obese. <input type="checkbox"/> poorly nourished. <input type="checkbox"/> thin. <input checked="" type="checkbox"/> well-built, muscular and fairly well-nourished.

Bennington, Chester

name

The skin is free of abrasions, bruises, lacerations, scars and burns.
or

There are ligature abrasions over the anterior neck, with a point of suspension behind the right ear.

Wrist scars are present. absent.

Tattoo(s) are:

not present.
 present and identified as fish, skeletons and flames on the arms, "LBJ" with a flower on the chest, a dragon with "LINKIN PARK" on the back, a dragon and butterfly on the calves

Rigor has presumably been altered/abolished.
 Rigor mortis is present.
 Livor mortis is fixed and in the legs. Abundant Tardieu spots are present.

The head is normocephalic and

covered by partly covered by

black hair.
 blond
 brown
 red
 _____/gray

There is

no
 complete
 frontal
 mid-biparietal
 occipital
 temporal

balding and the hair can be described as

Long _____ in.
 Short _____ in.
 Curly
 Straight
 Tightly Curled
 Wavy

Mustache is absent/~~present~~. Beard is absent/~~present~~ and described as _____.

Examination of the eyes reveals

Irides that appear to be brown in color and sclerae that are _____ without injection or jaundice.
 Corneal removal (eye bank).
 Eye shields in place.

There ~~are~~/^{rare} are no petechial hemorrhages of the conjunctivae of the lids and/or the sclerae. The oronasal passages are unobstructed.



Lower
 Upper
 Upper and lower

teeth are

absent.
 carious.
 partly absent and uncompensated.
 present.

Dentures are: _____

The neck is ~~unremarkable~~ shows a ligature abrasion corresponding to the belt.

There is is no chest deformity. There is no/an/a mildly increased anterior-posterior diameter.

The abdomen is

distended.
 flat.
 not unusual.
 obese.
 scaphoid.

The genitalia are those of an adult female/male.

The penis appears circumcised/uncircumcised.
 The external genitalia are without trauma or lesions.

The extremities show no edema, joint deformity, abnormal mobility, non-therapeutic punctures or needle tracks.
 or

EVIDENCE OF THERAPEUTIC INTERVENTION:

There is no evidence of any previous recent hospitalization.

The following are present and are in proper position:

- Airway mouth piece
- Central intravenous lines
- EKG Pads
- Endotracheal/nasotracheal tube
- Esophageal obturator
- Intravenous lines
- Nasogastric/orogastric tube
- Urinary catheter
- Other _____

CC#



Pennington, Chester
name

There are signs that the following surgical procedures have been done:

- _____ sided craniotomy.
- Cerebral ventricular pressure monitoring tube placement.
- Tracheostomy.
- _____ sided chest tube placement.
- _____ sided thoracotomy.
- Laparotomy.
- Peritoneal lavage procedure.
- Vascular cutdown procedure(s).
- Repair of injuries to _____.

Signs of cardiopulmonary resuscitation are as follows:

- Brown arc shaped paddle marks over the chest.
- Rib fracture located at _____.
- Serosanguineous pericardial fluid.
- Signs of intracardial injections.
- Focal areas of red hemorrhage in the posterior wall of the left ventricle.

There is evidence of old surgery. Scars are present at the _____ and the following organs are missing:

- 1.
- 2.
- 3.

There has ~~has not~~ been post mortem intervention for organ procurement which can be described as _____

EVIDENCE OF EXTERNAL TRAUMATIC INJURY:

Diagrammed on form(s) # 22

CLOTHING:

The body

is clothed

was not clothed

and I

did not see the clothing.

inspected the clothing.

CC#



Bennington, Chester
name

The clothing can be described as _____

INITIAL INCISION:

The body cavities are entered through

The standard coronal incision.
 The standard "Y" shaped incision.
 Additional incisions are _____

No foreign material is present in the mouth, upper airway and trachea.

EVIDENCE OF INTERNAL INJURIES:

Diagrammed on form(s) # _____

NECK:

The neck organs are are not removed en bloc with the tongue. No lesions are present nor is trauma of the gingiva, lips or oral mucosa demonstrated. There is no edema of the larynx. Both hyoid bone and larynx are intact and without fractures. No hemorrhage is present in the adjacent throat organs, investing fascia, strap muscles, thyroid or visceral fascia. There is hemorrhage of the left sterno mastoid muscle. There are are no prevertebral fascial hemorrhages. The tongue when sectioned shows no trauma/or _____



Bennington, Chester
name

CHEST/ABDOMINAL CAVITY:

The right/left/both pleural cavity/cavities contain(s) no fluid bleed, or adhesions/or

- Blood
- Fluid measuring _____ cc RT _____ LT _____

No tension pneumothorax is demonstrated. The parietal pleurae are intact.

The lungs are

- partly collapsed.
- poorly expanded.
- voluminous.
- well-expanded.

Soft tissues of the thoracic and abdominal walls

- are well-preserved.
- have early/late postmortem softening, discoloration and crepitation.

The subcutaneous fat of the

- abdominal wall measures _____
- chest wall measures _____

~~Breasts are examined and sectioned in usual manner and show no abnormalities/or~~

The organs of the abdominal cavity have a normal arrangement and none are absent. There is no fluid collection. The peritoneal cavity is without evidence of peritonitis. There are no adhesions.

SYSTEMIC AND ORGAN REVIEW

The following observations are limited to findings other than injuries, if described above.

MUSCULOSKELETAL SYSTEM:

- No abnormalities of the bony framework or muscles are present.
- Kyphosis/scoliosis
- Wasting
- Other _____

CARDIOVASCULAR SYSTEM:

The aorta is elastic/fairly elastic/inelastic and of even caliber throughout with vessels distributed normally from it.

The abdominal/thoracic aorta has

<input type="checkbox"/> discrete plaques that are not elevated.
<input checked="" type="checkbox"/> lipid streaking.
<input type="checkbox"/> <u>minimal/moderate/severe</u> atherosclerosis.

There is no tortuosity or widening of the thoracic segment. The abdominal aorta has

<input type="checkbox"/> diffuse
<input type="checkbox"/> extensive
<input type="checkbox"/> focal
<input checked="" type="checkbox"/> minimal

atherosclerosis
with/without

<input type="checkbox"/> focal	<input type="checkbox"/> intimal
<input type="checkbox"/> marked	<input type="checkbox"/> mural
<input type="checkbox"/> minimal	<input type="checkbox"/> ulceration and/or
<input type="checkbox"/> moderate	

calcification.

There is is no dilation of the lower abdominal segment. No An intact aneurysm is present measuring _____ cm. The major branches of the aorta show no abnormality.

Within the pericardial sac there

<input type="checkbox"/> are _____ cc. of _____ fluid.
<input checked="" type="checkbox"/> is a minimal amount of serous fluid.

The heart weighs 470 grams.

It has

<input checked="" type="checkbox"/> a normal configuration. <input type="checkbox"/> an infantile configuration. <input type="checkbox"/> biventricular hypertrophy. <input type="checkbox"/> left ventricular hypertrophy. <input type="checkbox"/> right ventricular hypertrophy. <input type="checkbox"/> _____	The right ventricle is _____ cm thick and the left ventricle is _____ cm thick.
---	--

The chambers are normally developed and are without mural thrombosis. The valves are thin, leafy and competent or

Circumference of valve rings are:

T.V. _____ cm	A.V. _____ cm
P.V. _____ cm	M.V. _____ cm

There is/are

<input type="checkbox"/> endocardial hemorrhages of _____.
<input type="checkbox"/> hemoglobin staining of the endocardium.
<input checked="" type="checkbox"/> no endocardial discoloration.

There

<input type="checkbox"/> is/are	<input type="checkbox"/> infarct(s)
<input checked="" type="checkbox"/> is/are no	<input checked="" type="checkbox"/> lesion(s)

of the myocardium.



name Bennington, Chester

There is is no abnormality of the apices of the papillary musculature.
 atrophy
 hemorrhagic necrosis
 necrosis
 scarring

There are are no defects of the septum. The great vessels enter and leave in a normal fashion.

The ductus arteriosus cannot be probed.
 is obliterated.
 is widely patent.
 measures _____.

The coronary ostia
 are narrowed.
 are widely patent.
 The left coronary artery is the dominant vessel.
 The right coronary artery is the dominant vessel.
 There is a balanced pattern of coronary artery distribution.
 There is a normal pattern of coronary artery distribution.

There is are extensive atherosclerosis with up to 25 %
 minimal atherosclerotic plaque(s) with mild to moderate
 no coronary segmental without
 segmental with severe
 narrowing of the anterior descending branch of the left coronary artery.
 occlusion circumflex branch of the left coronary artery.
 stenosis left/right coronary artery.
 major coronary arteries.

No focal endocardial, valvular or myocardial lesions are seen. The blood within the heart and large blood vessels is liquid/clotted.

RESPIRATORY SYSTEM:

An extremely large amount of blood is
 Considerable bloody fluid is
 Moderate edema is
 No exudate is
 Scant gastric material is
 glairy fluid is
 secretions are
found in the lower bronchial passages.
 upper respiratory



Bennington, Chester
name

The mucosa

<input type="checkbox"/> has _____ postmortem discoloration. <input type="checkbox"/> is focally hemorrhagic. <input checked="" type="checkbox"/> is intact and pale. <input type="checkbox"/> is severely injected throughout. <input type="checkbox"/> is ulcerated.
--

The lungs are

<input type="checkbox"/> atelectatic <input type="checkbox"/> crepitant <input type="checkbox"/> emphysematous <input checked="" type="checkbox"/> subcrepitant	and there is	<input checked="" type="checkbox"/> dependent congestion. <input type="checkbox"/> postmortem softening.
--	--------------	---

The left lung weights	<u>540</u>	grams.
The right lung weighs	<u>720</u>	grams.

The visceral pleurae

<input type="checkbox"/> are punctured. <input type="checkbox"/> are scarred. <input checked="" type="checkbox"/> are smooth and intact. <input type="checkbox"/> are thickened. <input type="checkbox"/> contain marginal blebs.

The parenchyma is

<input checked="" type="checkbox"/> congested. <input type="checkbox"/> congested and edematous. <input type="checkbox"/> consolidated. <input type="checkbox"/> hemorrhagic. <input type="checkbox"/> nodular.

<input checked="" type="checkbox"/> The pulmonary vasculature is without thromboembolism. <input type="checkbox"/> Thromboemboli <u>are/are not</u> present in the distal tertiary branches. <input type="checkbox"/> Thromboemboli <u>are/are not</u> present in the extrapulmonic portions of the pulmonary artery.

GASTROINTESTINAL SYSTEM:

The esophagus is/has

<input type="checkbox"/> corrosion. <input checked="" type="checkbox"/> intact throughout. <input type="checkbox"/> terminal postmortem erosion. <input type="checkbox"/> ulceration. <input type="checkbox"/> varices.

The stomach is/is not distended by _____ . It contains 90 cc of clear fluid .
 The mucosa is intact without hemorrhage or ulceration. .



Portions of tablets and capsules cannot be discerned in the stomach.

Residual medication materials seen in the stomach _____

The external and in-situ appearance of the small intestine and colon are unremarkable.

The small intestine and colon are opened along the anti-mesenteric border and _____
no mucosal lesions are present.

The small intestine and colon are examined by inspection, palpation and multiple incisions and _____

The appendix is present/absent surgically.

The pancreas occupies a normal position. There is no

early autolysis.

necrosis.

trauma.

The parenchyma is lobular and firm. The pancreatic ducts are/are not ectatic and there is no parenchymal calcification.

HEPATOBIILIARY SYSTEM:

The liver weighs 1900 grams,

is enlarged.

is of average size.

is smaller than normal

and is

red-brown.

tan-brown.

yellow-tan.

The capsule is

intact

thickened

thin

and the consistency of the parenchyma is

firm.

greasy.

increased in resistance.

soft.

The cut surface is

macronodular.

micronodular.

smooth.

fatty.

There is

a normal lobular arrangement.

acute passive congestion.

chronic passive congestion.

The gallbladder is

<input type="checkbox"/> absent.
<input checked="" type="checkbox"/> present.

The wall is

<input type="checkbox"/> thickened and rigid.
<input checked="" type="checkbox"/> thin and pliable.

It contains

<input checked="" type="checkbox"/> <u>~5</u> cc of bile
<input type="checkbox"/> no bile

and

<input type="checkbox"/> calculi which are
<input type="checkbox"/> mixed.
<input type="checkbox"/> pure.
<input checked="" type="checkbox"/> no calculi.

There is no obstruction or dilation of the extrahepatic ducts. The periportal lymph nodes are enlarged/not enlarged.

URINARY SYSTEM:

The left kidney weighs 170 grams. The right kidney weighs 200 grams.

The kidneys are normally situated and the capsules strip easily/with difficulty, revealing a surface that is smooth and dark red.

The corticomedullary demarcation is

<input type="checkbox"/> obliterated.
<input type="checkbox"/> obscured by congestion.
<input checked="" type="checkbox"/> preserved.

The pyramids are are not remarkable. The peripelvic fat is is not increased. The ureters are without dilation or obstruction and pursue their normal course.

The urinary bladder is

<input type="checkbox"/> contracted.
<input type="checkbox"/> distended.
<input type="checkbox"/> trabeculated.
<input checked="" type="checkbox"/> unremarkable.

It contains

<input checked="" type="checkbox"/> <u>40</u> cc of	<input checked="" type="checkbox"/> clear
<input checked="" type="checkbox"/> amber	<input type="checkbox"/> cloudy
<input type="checkbox"/> brown	
<input type="checkbox"/> hemorrhagic	
<input type="checkbox"/> no urine.	

urine.

The urine is is not tested by the dipstick method and the results are _____

GENITAL SYSTEM: (Cross or X out one - fill in the other.)

Female:

The uterus is

<input type="checkbox"/> asymmetrical
<input type="checkbox"/> surgically absent as are adnexa
<input type="checkbox"/> symmetrical

and the uterine cavity is

<input type="checkbox"/> enlarged.
<input type="checkbox"/> not enlarged.

CC#



Bennington, Chester
name

The fallopian tubes are unremarkable/or

The endometrium is _____

The cervix and vagina have a normal appearance for the age.

The ovaries are

- cystic.
- large.
- nodular and solid.
- not identified.
- small and atrophic.
- normal for the age.

Male:

The prostate is

- enlarged.
- without enlargement or nodularity.

Both testes are in the scrotum are unremarkable and without trauma/or

HEMOLYMPHATIC SYSTEM:

The spleen weighs 170 grams and is enlarged/of average size.

The capsule is

- intact.
- lacerated.
- smooth.
- wrinkled.

The parenchyma is

- dark red.
- firm.
- mushy.
- pale.

There is an/no increased follicular pattern.

- Lymph nodes throughout the body are small and inconspicuous.
- There is generalized lymph node prominence and enlargement.
- There is focal enlargement of lymph nodes in the following areas: _____

The bone is brittle/not remarkable.

The bone marrow of the vertebra/rib is

- red and moist.
- the usual appearance for the age.
- unremarkable.

ENDOCRINE SYSTEM:

The thyroid is

<input type="checkbox"/> decreased in size.	<input type="checkbox"/>
<input type="checkbox"/> enlarged.	
<input type="checkbox"/> mediastinal.	
<input type="checkbox"/> nodular.	
<input checked="" type="checkbox"/> unremarkable.	

The parathyroid glands are not identified.

The adrenals are

<input type="checkbox"/> atrophic.	<input type="checkbox"/>
<input type="checkbox"/> autolyzed.	
<input type="checkbox"/> hemorrhagic.	
<input checked="" type="checkbox"/> intact without necrosis or hemorrhage.	
<input type="checkbox"/> necrotic.	
<input type="checkbox"/> unremarkable.	

Thy thymus is

<input checked="" type="checkbox"/> not identified.
<input type="checkbox"/> the usual appearance for the age.
<input type="checkbox"/> unremarkable.

and weighs _____ grams.

The pituitary gland is of normal size/unremarkable.

SPECIAL SENSES:

The eyes are are not dissected. The middle and inner ear are are not dissected.

HEAD AND CENTRAL NERVOUS SYSTEM:

There is is no subcutaneous and/or subgaleal hemorrhage in the scalp. ~~The hemorrhage does/does not extend into the orbits, and/or the temporal muscles.~~ The external periosteum and dura mater are stripped showing no fractures of the calvarium or base of the skull. There are no tears of the dura mater. There is is no epidural, subdural, or subarachnoid hemorrhage _____

The brain weighs 1530 grams. The leptomeninges are thin and transparent. A normal/flattened convolutionary pattern is observed. Coronal sectioning demonstrates a uniformity of cortical gray thickness. The cerebral hemispheres are symmetrical. There is no softening, discoloration, or hemorrhage of the white matter. The basal ganglia are intact. Anatomic landmarks are preserved. Cerebral contusions are are not present.



Bennington, Chester
name

The ventricular system

- has a normal appearance
- is symmetrical
- is unremarkable

without dilation and/or distortion.

Pons, medulla and cerebellum are unremarkable. There is no evidence of uncal or cerebellar herniation. Vessels at the base of the brain have a normal pattern of distribution. There are no aneurysms. The cranial nerves are intact, symmetrical, and normal in size, location and course.

The cerebral arteries

- are moderately sclerotic.
- are without arteriosclerosis.
- have advanced/mild arteriosclerosis.
- have arteriosclerosis at points of bifurcation.

SPINAL CORD:

- The entire cord is is not dissected.
- A segment of
 - cervical
 - lumbar
 - thoracic
 spinal cord is examined and is unremarkable/or _____
- The spinal fluid is clear.

NEUROPATHOLOGY:

The brain and/or spinal cord is placed in formalin solution for further fixation and later examination.

HISTOLOGIC SECTIONS:

Representative sections from various organs are preserved in one two/three storage jar(s) in 10% formalin. Sections of _____

are submitted for slides.

The slide key is _____

TOXICOLOGY:

- Bile
- Blood
- Liver tissue
- Stomach contents
- Urine
- Vitreous humor
- _____

have been submitted to the lab.

- A comprehensive
- A homicide
- A traffic
- A drugs of abuse
- No

screen was requested. with zolpidem.

CC#



Bennington, Chester
name

SPECIAL PROCEDURES:

Biopsies of _____

Cultures of _____

have been submitted to the lab.

Anesthesiology

Anthropology

Criminalistics

Odontology

Ophthalmology

Pulmonary

Surgical

consultation(s) was/were requested.

PHOTOGRAPHY:

At scene photos are/are not available.

No photos are taken.

Photographs have been taken prior to and/or during the course of the autopsy.

RADIOLOGY:

The body is fluoroscoped _____.

No x-rays are obtained.

The body is fluoroscoped and x-rays are taken of the head/chest/ _____.

WITNESSES:

None _____ of _____

DA

LAPD _____ witnessed the autopsy.

LASO

DIAGRAMS USED:

Diagram form(s) # 20, 22 were used during the performance of the autopsy. The diagrams are not intended to be facsimiles.

CC#



Remington, Chester
name

OPINION:

Autopsy findings are characteristic of suicidal hanging. There was a history of suicidal ideation.

SIGNATURE
RESIDENT IN PATHOLOGY



SIGNATURE
DEPUTY MEDICAL EXAMINER

PRINT NAME
DATE:

Christopher Rogers

PRINT NAME
DATE:

7-21-17

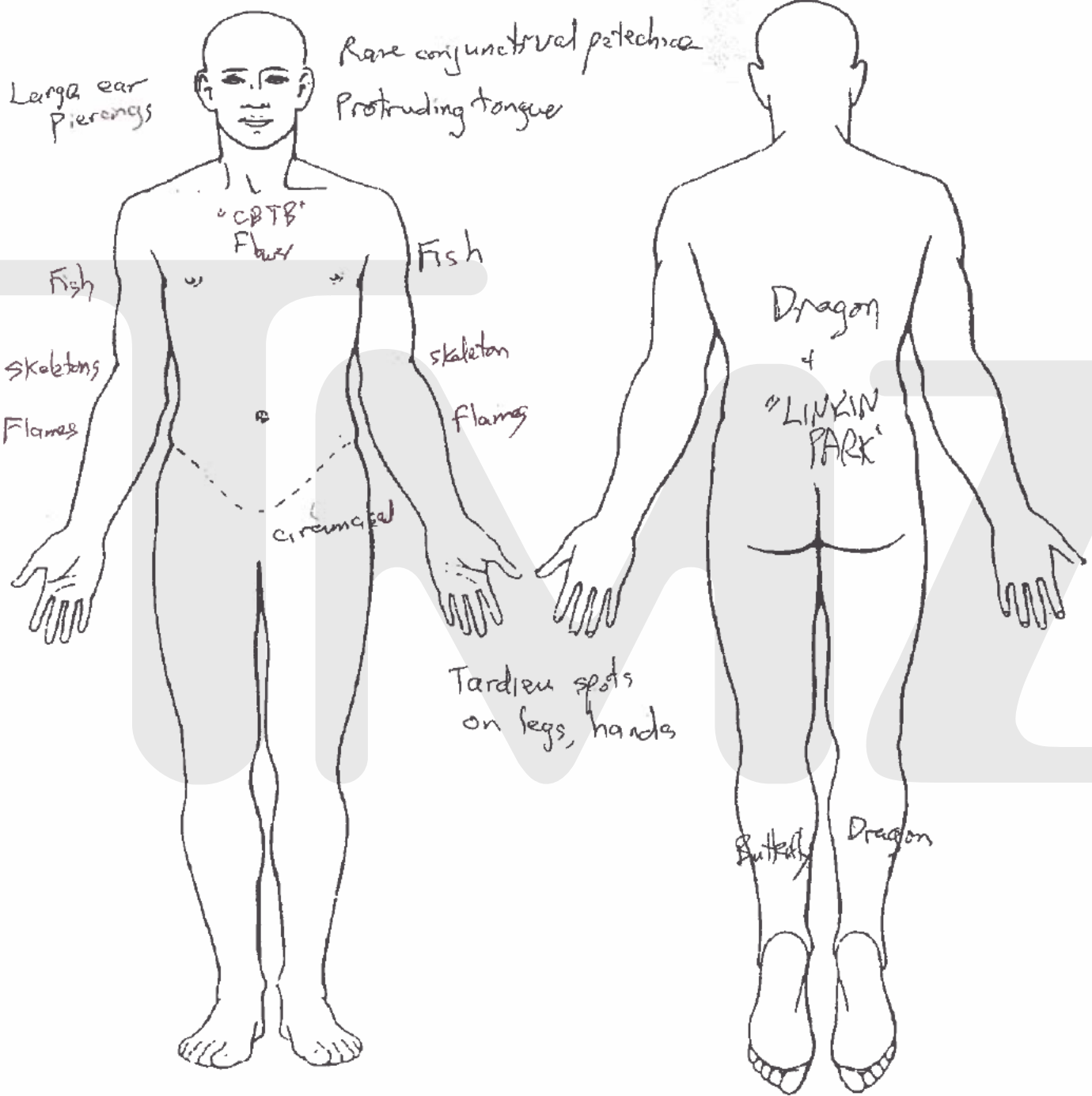
COMMON ABBREVIATIONS

Ab	=	Abnormal	NGT	=	Nasogastric Tube
Abr	=	Abrasion	NPD	=	No Pathologic Diagnosis
AM	=	Ante Mortem	NPW	=	Needle Puncture Wound
AV	=	Aortic Valve	NTFP	=	No Evidence of Any Significant Trauma or Foul Play
&	=	And	NL	=	Normal
B	=	Blood	NE	=	Not Examined
Blk	=	Black	NW	=	Not Weighed
Blu	=	Blue	#	=	Number
Brn	=	Brown	∅	=	Negative or No
C	=	Congestion/Contusion	OS	=	Old Scar
CT	=	Chest Tube	P	=	Pictorial or Path
D	=	Direction	PER	=	Pupils Equal & Round
Dx	=	Diagnosis	PM	=	Post Mortem
E	=	Ecchymosis	PV	=	Pulmonic Valve
EDH	=	Epidural Hemorrhage	Q	=	Quadrant
EOT	=	Exclusive of Trauma	R	=	Right
En	=	Entrance	ROM	=	Right of Middle
ETT	=	Endotracheal Tube	RV	=	Right Ventricle
Ex	=	Exit	Rx	=	Treatment
♀	=	Female	S	=	Scar
FP	=	Fresh Puncture	SAH	=	Subarachnoid Hemorrhage
Fx	=	Fracture	SDH	=	Subdural Hemorrhage
Grn	=	Green	SGH	=	Subgaleal Hemorrhage
Gry	=	Gray	Sh	=	Shaved
GSW	=	Gunshot Wound	SP	=	Status Post
H	=	Hemorrhage	STH	=	Soft Tissue Hemorrhage
Hzi	=	Hazel	SW	=	Stab Wound
I	=	Incision	TOH	=	Top of Head
ICS	=	Intercostal Space	TV	=	Tricuspid Valve
ICP	=	Intracranial Pressure Monitor	W	=	Wound
IVL	=	Intravenous Line	WDWN	=	Well Developed, Well Nourished
LAD	=	Left Anterior Descending Coronary Artery	<u>c</u>	=	With
Lat	=	Lateral	<u>s</u>	=	Without
L	=	Left or Laceration	WNL	=	Within Normal Limits
LOM	=	Left of Middle	WT	=	Weight
LV	=	Left Ventricle			
♂	=	Male			
M	=	Middle or Midline			
MV	=	Mitral Valve			

20

2017- [REDACTED]
BENNINGTON, CHESTER
SUI

b2



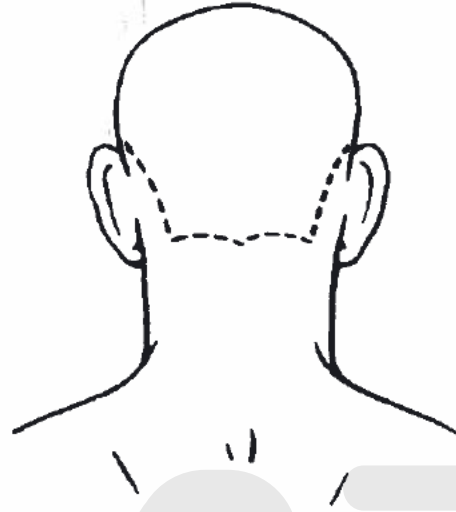
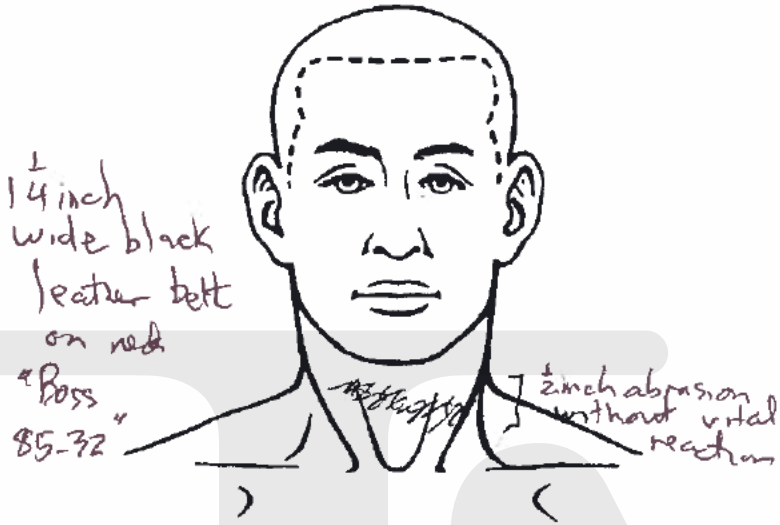
Date

[REDACTED] 1055
7-24-17 M.D.
Deputy Medical Examiner

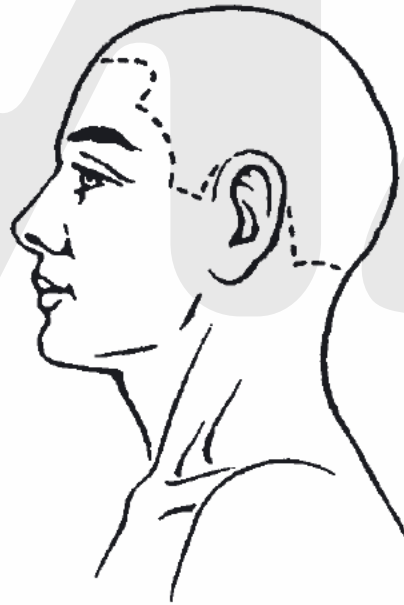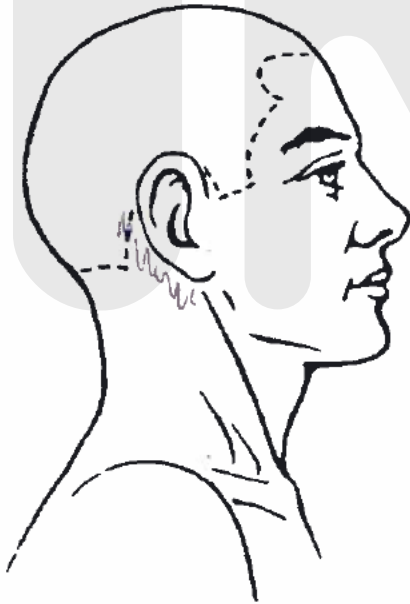
22

2017-
BENNINGTON, CHESTER
SUI

62



Point of suspension behind R. ear



Date

[Redacted]

1055
7-21-17 M.D.

Deputy Medical Examiner

16

2017-
BENNINGTON, CHESTER
SUI

b2

EXTERNAL EXAM

Sex Male
Race Caucasian
Age 41
Height 69
Weight 167
Hair Brown
Eyes Brown
Sclera Few petechiae

Teeth
Mouth
Tongue
Nose Normal

Chest
Breasts
Abdomen
Scar - None
Genitals - Circumcised
Edema
Skin Normal
Decubitus

HEART Wt. 470

Pericardium
Hypertrophy
Dilation
Muscle
Valves
Coronaries
RV
Septum
LV
Septum
minimal atherosclerosis of LAD

AORTA
VESSELS Normal

LUNGS Wt.

R 720
L 540
Adhesions
Fluid
Atelectasis
Oedema
Congestion
Consolidation Normal
Bronchi
Nodes

PHARYNX
TRACHEA
THYROID
THYMUS
LARYNX
HYOID
ABDOMINAL WALL FAT

PERITONEUM

Fluid
Adhesions Normal

LIVER Wt. 1900

Capsule
Lobules
Fibros Normal
G B
Calculus
Bile ducts

SPLEEN Wt. 170

Color
Consistency
Capsule
Malpiment Normal

PANCREAS

ADRENALS

KIDNEYS Wt.

R 200
L 170
Capsule
Cortex
Vessels Normal
Pelvis
Ureters

BLADDER 40 gm urine

GENITALIA

Prostate
Testes Normal
Uterus
Tubes
Ovaries

OESOPHAGUS Normal

STOMACH

Contents 90 gm fluid

DUOD. & SM. INT.

APPENDIX

LARGE INT.

ABDOM. NODES

SKELETON

Spine
Marrow
Rib Cage
Long bones
Pelvis Normal

SCALP
CALVARIUM } Normal
BRAIN Wt. 1530

Dura
Fluid
Ventricles
Vessels
Middle ears Normal
Other
PITUITARY

SPINAL CORD

TOXICOLOGY SPECIMENS
Blood, bile, liver, stomach
contents, urine, vitreous

SECTIONS FOR
HISTOPATHOLOGY
Stool jar

MICROBIOLOGY

DIAGRAMS 20, 22
X-RAYS

OTHER PROCEDURES

GROSS IMPRESSIONS
See Form 12

Date 7-21-17

Time 1210

Deputy Medical Examiner





FORENSIC SCIENCE LABORATORIES



Laboratory Analysis Summary Report

Rogers, Christopher M.D.

Deputy Medical Examiner

PendingTox

The following results have been technically and administratively reviewed and are the opinions and conclusions of the Analyst:

Coroner Case Number: 2017- [REDACTED] **Decedent:** BENNINGTON, CHESTER CHARLES

<u>SPECIMEN</u>	<u>SERVICE</u>	<u>DRUG</u>	<u>RESULT</u>	<u>ANALYST</u>
Blood, Femoral				
	Alcohol-GC/FID-HS	Ethanol	0.054 g%	S. DeQuintana
Blood, Heart				
	Alcohol-GC/FID-HS	Ethanol	0.053 g%	S. DeQuintana
	Bases-GC/NPD &/or MS	Zolpidem	ND	B. Ciullo
	ELISA-Immunoassay	Barbiturates	ND	J. Gadway
	ELISA-Immunoassay	Cocaine and Metabolites	ND	J. Gadway
	ELISA-Immunoassay	Fentanyl	ND	J. Gadway
	ELISA-Immunoassay	Methamphetamine & MDMA	PP	J. Gadway
	ELISA-Immunoassay	Opiates: Codeine & Morphine	ND	J. Gadway
	ELISA-Immunoassay	Opiates: Hydrocodone & Hydromorphone	ND	J. Gadway
	ELISA-Immunoassay	Phencyclidine	ND	J. Gadway
	Sympath. Amines-GC/MS	Amphetamine	ND	D. Levanas
	Sympath. Amines-GC/MS	Methamphetamine	ND	D. Levanas
	Sympath. Amines-GC/MS	Methylenedioxyamphetamine (MDA)	ND	D. Levanas
	Sympath. Amines-GC/MS	Methylenedioxymethamphetamine (MDMA)	ND	D. Levanas
Urine				
	Sympath. Amines-GC/MS	Amphetamine	ND	D. Levanas
	Sympath. Amines-GC/MS	Methamphetamine	ND	D. Levanas
	Sympath. Amines-GC/MS	Methylenedioxyamphetamine (MDA)	ND	D. Levanas
	Sympath. Amines-GC/MS	Methylenedioxymethamphetamine (MDMA)	ND	D. Levanas
Vitreous				
	Alcohol-GC/FID-HS	Ethanol	0.059 g%	S. DeQuintana

ER 1018-17

Coroner Case Number: 2017- [REDACTED] Decedent: BENNINGTON, CHESTER CHARLES

<u>SPECIMEN</u>	<u>SERVICE</u>	<u>DRUG</u>	<u>RESULT</u>	<u>ANALYST</u>	
Legend:					
	mg/dL	Milligram per Deciliter	PP	Presumptive Positive	
g	Grams	mg/L	Milligram per Liter	QNS	Quantity Not Sufficient
g%	Gram Percent	ND	Not Detected	ug	Micrograms
Inc.	Inconclusive	ng/g	Nanograms per Gram	ug/g	Micrograms per Gram
mg	Milligrams	ng/mL	Nanograms per Milliliter	ug/mL	Microgram per Milliliter

In accordance with the Department's Evidence Retention Policy, the blood specimen(s) will be retained for one-year and all other specimens for six-months from Autopsy.

Administratively reviewed by: [REDACTED]

Sarah Buxton de Quintana,
Senior Criminalist TOXICOLOGY
[REDACTED]

1	APPARENT MODE SUICIDE	CASE NO 2017 [REDACTED]
	SPECIAL CIRCUMSTANCES Media Interest	CRYPT

LAST, FIRST MIDDLE BENNINGTON, CHESTER CHARLES	AKA	#
--	-----	---

ADDRESS [REDACTED]	CITY [REDACTED]	STATE [REDACTED]	ZIP [REDACTED]
-----------------------	--------------------	---------------------	-------------------

SEX MALE	RACE APPEARS CAUCASIAN	DOB 3/20/1976	AGE 41	HGT 69 in.	WGT 167 lbs.	EYES BROWN	HAIR BROWN	TEETH ALL NATURAL TEETH	FACIAL HAIR UNKNOWN	ID VIEW Yes	CONDITION FAIR
-------------	---------------------------	------------------	-----------	---------------	-----------------	---------------	---------------	----------------------------	------------------------	----------------	-------------------

MARK TYPE	MARK LOCATION	MARK DESCRIPTION
TATTOO	LOW BACK	"LINKIN PARK"
TATTOO	CHEST	BANNERS WITH INITIALS
TATTOO	BOTH ARMS	VARIOUS IMAGES

NOK [REDACTED]	ADDRESS [REDACTED]	CITY [REDACTED]	STATE [REDACTED]	ZIP [REDACTED]
-------------------	-----------------------	--------------------	---------------------	-------------------

RELATIONSHIP WIFE	PHONE [REDACTED]	NOTIFIED BY	DATE 7/20/2017	TIME
----------------------	---------------------	-------------	-------------------	------

SSN [REDACTED]	STATE CA	PENDING BY
-------------------	-------------	------------

ID METHOD FINGERPRINTS FROM FBI

LA #	MAIN #	CI #	FBI #	MILITARY #	POB
------	--------	------	-------	------------	-----

IDENTIFIED BY NAME (PRINT) FBI ONLY	RELATIONSHIP NONE	PHONE	DATE 7/20/2017	TIME 16:46
--	----------------------	-------	-------------------	---------------

PLACE OF DEATH / PLACE FOUND RESIDENCE	ADDRESS OR LOCATION [REDACTED]	CITY [REDACTED]	ZIP [REDACTED]
---	-----------------------------------	--------------------	-------------------

PLACE OF INJURY RESIDENCE	AT WORK No	DATE	TIME	LOCATION OR ADDRESS [REDACTED]	ZIP [REDACTED]
------------------------------	---------------	------	------	-----------------------------------	-------------------

DOD 7/20/2017	TIME 09:08	FOUND OR PRONOUNCED BY LACFD ENGINE 2
------------------	---------------	--

OTHER AGENCY INV. OFFICER [REDACTED]	PHONE [REDACTED]	REPORT NO. [REDACTED]	NOTIFIED BY [REDACTED]	NO
---	---------------------	--------------------------	---------------------------	----

TRANSPORTED BY	TO LOS ANGELES FSC	DATE	TIME
----------------	-----------------------	------	------

FINGERPRINTS?	Yes	CLOTHING	Yes	PARPT	No	MORTUARY	
MED. EV.	Yes	INVEST PHOTO #	51	SEAL TYPE	NOT SEALED	HOSP RPT	No
PHYS. EV.	No	EVIDENCE LOG	Yes	PROPERTY?	Yes	HOSP CHART	No
SUICIDE NOTE	No	GSR NO		RCPT. NO.	297171	PF NO	

SYNOPSIS
THE DECEDENT HAD A HISTORY OF ALCOHOLISM, DEPRESSION, SUICIDAL IDEATIONS, AND PRIOR SUICIDE ATTEMPTS. HE WAS LAST KNOWN ALIVE ON THE NIGHT OF 07/19/2017. ON 07/20 AROUND 0850 HOURS HIS HOUSEKEEPER DISCOVERED HIM UNRESPONSIVE AND HANGING WITH A LIGATURE AROUND HIS NECK IN HIS BEDROOM. PARAMEDICS PRONOUNCED DEATH ON SCENE WITHOUT MEDICAL INTERVENTION. THERE WAS NO SUICIDE NOTE FOUND. THERE WAS NO FOUL PLAY SUSPECTED.

VANANDA CHOLAKIANS 604323	[REDACTED]	INVESTIGATOR	DATE 7/20/2017	RECEIVED BY [REDACTED]	DATE 07-20-2017	TIME 18:05	TIME 18:3
------------------------------	------------	--------------	-------------------	---------------------------	--------------------	---------------	--------------



County of Los Angeles, Department of Coroner
Investigator's Narrative



Case Number: 2017- [REDACTED]

Decedent: BENNINGTON, CHESTER CHARLES

Information Sources:

- 1) Officer A. Belda #731, Palos Verdes Estates Police Department. [REDACTED]
- 2) [REDACTED] decedent's employee. [REDACTED]
- 3) [REDACTED] decedent's wife. [REDACTED]

Investigation:

On 07/20/2017 at 0915 hours Officer Belda reported this apparent suicide death to the Los Angeles County Medical Examiner – Coroner. I was assigned this field case at 0925 hours by Lieutenant Smith. I arrived on scene at 1050 hours. I concluded my field investigation and cleared the scene at 1205 hours. LACMEC Assistant Chief E. Winter and Palos Verdes Estates PD Corporal Robinson #716 were also present on scene. Forensic Attendant J. Killen transported the decedent to the Forensic Science Center.

Location:

Injury and Death: [REDACTED]

Informant/Witness Statements:

On 07/20/2017 while on scene I conducted an interview with Officer Belda and he related to me the following information. The decedent was last seen alive by the housekeeper, [REDACTED] at his residence at the above location on 07/19/2017 around 2230 hours and nothing out of the ordinary was reported. She left the residence at that time and returned on 07/20/2017 around 0830 hours. Around 0850 hours she discovered him unresponsive and hanging with a ligature around his neck in his bedroom. She dialed 911 and Los Angeles County Fire Department Engine 2 responded. Captain Avedissian pronounced death on scene at 0908 hours without medical intervention. Paramedics removed a prescription bottle from the nightstand and placed it on a dresser. His wife, [REDACTED] was notified by [REDACTED] and Officer Belda also spoke with her from the scene. The decedent had reportedly returned from a family vacation in Arizona on the night of 07/19. [REDACTED] was still in Arizona and was en route to Los Angeles after being notified.

On 07/20/2017 while on scene I conducted an interview with [REDACTED] and she related to me the following information. She had known and was employed by the decedent for approximately two years. She routinely came to the residence daily and let herself in with a key. On 07/19/2017 the decedent arrived home around 2230 hours while she was in the bathroom. She did not see him enter the house and saw him when he was already upstairs after he had put his bags away. There was nothing out of the ordinary reported about his behavior. She left the residence approximately five minutes later and he told her that he would be leaving for work early the next morning, around 0430 hours. On 07/20 around 0830 hours she arrived at the residence and let herself in with her key. She did not hear anything and assumed he had already left. Around 0845 hours an Uber vehicle pulled into the driveway and she went upstairs to check if he was there. He did not answer knocks on the door and she let herself into the unlocked bedroom. She discovered him unresponsive and dialed 911. She did not move the decedent or any items in the room.

On 07/20/2017 I conducted a telephone interview with the decedent's wife, [REDACTED] and she related to me the following information. The decedent had a history of depression, suicidal ideations, and past suicide attempts. He would have suicidal ideations after consuming alcohol. In 2006 he was consuming alcohol heavily and threatened to commit suicide. He had left their home with a gun and she had to call the police to find him. [REDACTED]

[REDACTED]



County of Los Angeles, Department of Coroner
Investigator's Narrative



Case Number: 2017 [REDACTED]

Decedent: BENNINGTON, CHESTER CHARLES

[REDACTED] His primary medical doctor was Dr. William Lang. The decedent had been prescribed antidepressants in the past but had not used them in over a year. He also used Ambien occasionally. He was currently in an outpatient treatment program and was supposed to be sober. He flew home from their family cabin in Arizona on the night of 07/19 because he had a work event scheduled for 07/20. She last communicated with him via text message on the night of 07/19 after his plane landed in Los Angeles. She stated the Uber vehicle that arrived on 07/20 was sent by the band management. She stated the journal found on the nightstand was one he maintained for his outpatient treatment program. She also stated that she did not find a suicide note in his phone. I also asked her about the fingernail pieces and she stated that he often does that when anxious.

Scene Description:

The scene was the upstairs bedroom in a home located at the above location. The decedent was observed hanging with a ligature around his neck. The ligature was a black leather belt with a metal buckle engraved with "Hugo Boss". The belt was looped around the decedent's neck then through the buckle, before extending up towards the door frame. The belt passed between the top edge of a door and the door frame. The buckle was at the posterior of the decedent's neck. The height of the door frame was 65 inches. From the floor to the level of the buckle at the decedent's neck was 48 inches. The ligature measured from the buckle at the neck to the tip of the belt was 28 inches. In the decedent's front left pocket was an American Airlines folded boarding pass in his name for flight 640 from Phoenix to Los Angeles. In his front right pocket were coins.

To the left of the decedent was a nightstand on top of which was an iPhone that was password protected. The passcode was required to enable Touch ID. Underneath the phone there were multiple fingernail pieces. The door of the nightstand was ajar. There was another iPhone (or iPod) inside the nightstand but it was powered off. The lamp on the nightstand was powered on. There were also fingernail pieces on a table attached to a sofa in the bedroom.

On a dresser in the room was a prescription for Zolpidem 10mg containing one tablet broken in half. It was prescribed to [REDACTED] was filled on 06/29/2017. It had been removed from the nightstand adjacent to the decedent by paramedics, as reported by Officer Belda. Also on this dresser was a one pint glass bottle of Corona, less than half full.

On the counter of an attached bathroom was an empty glass bottle of Stella Artois, two bottle caps (Stella and Corona), two pairs of glasses, a wallet, and a towel. There was an empty 7-Eleven bag on the floor of the bathroom. There was a gray shirt in the hamper in the bathroom. The trash can in the bathroom was empty.

Also in the bedroom I discovered a journal with handwritten apparent biography that was not dated. There was also a typed apparent biography in another nightstand. [REDACTED]

[REDACTED]

The door the decedent was in front of led to a small room, with two luggage bags on the floor containing clothing and shoes.

Evidence:

On 07/20/2017 at 1140 hours I collected medical evidence from the scene and later booked it into the evidence department at the Forensic Science Center. The ligature was left with the decedent.



County of Los Angeles, Department of Coroner
Investigator's Narrative



Case Number: 2017-██████████

Decedent: BENNINGTON, CHESTER CHARLES

Body Examination:

The decedent was an adult Caucasian male observed hanging with a ligature around his neck in the above described scene. His arms were extended straight down. His legs were flexed at the knees with both feet touching the carpeted floor. He was clad in blue jeans, a brown belt that was unbuckled, and black underwear. He had short brown hair, brown eyes, unshaven facial hair, and natural teeth. His tongue was clenched between his teeth and slightly protruding from the mouth. The bottom lip and tip of the tongue were slightly dehydrated. There was thick emesis from the nares and residue of this on the chest. There were no petechiae noted. The decedent had multiple tattoos including: rose with branches and initials on banners on the chest; flames on both forearms; "Linkin Park" on the low back; various image on the back. Rigor mortis observed at 1125 hours was rated a 3 throughout the body. Livor mortis observed at 1128 hours was consistent with the found position, on the distal arms and legs, and blanched with hard fingertip pressure. There were also apparent Tardieu spots on the feet.

Identification:

On 07/20/2017 at 1646 hours, the decedent was positively identified as Chester Bennington (DOB 03/20/1976) by Federal Bureau of Investigations fingerprint comparison. His California Driver License #D6950703 identified him as Chester Charles Bennington.

Next of Kin Notification:

On 07/20/2017 the decedent's wife and legal next of kin, ██████████ was notified of the death by ██████████ their housekeeper. I confirmed notification with ██████████ telephonically on 07/20/2017.

Tissue Donation:

Family members did not consent to tissue donation by the time of report completion.

Autopsy Notification:

There was no request for autopsy notification.

████████████████████
████████████████████

INVESTIGATOR CHOLAKIANS
#604323

████████████████████
████████████████████

SUPERVISOR # 602086
Oliver Kim

07/20/2017

Date of Report

6

WAS ORIGINAL SCENE DISTURBED BY OTHERS? Y [] N [X]
 IF YES, NOTE CHANGES IN NARRATIVE FORM #3.
 DATE 07/20/2017

2017- [REDACTED]
 BENNINGTON, CHESTER
 SUICIDE
 07/20/2017
 THERMOMETER # _____

AMBIENT #1 _____ °F
 AMBIENT #2 _____ °F
 WATER _____ °F

NOT TAKEN

TIME _____
 TIME _____
 TIME _____
 TIME _____

LIVER TEMPERATURE #1 _____ °F

LIVER TEMPERATURE #2 _____ °F

DATE & TIME FOUND 07/20/2017 0908HRS LAST KNOWN ALIVE 07/19/2017

APPROX. AGE 41 SEX M EST. HEIGHT 69 EST. WEIGHT 167. CLOTHED? YES [X] NO [] IF YES, DESCRIBE:
 BLUE JEANS, BLACK UNDERWEAR, BROWN BELT.

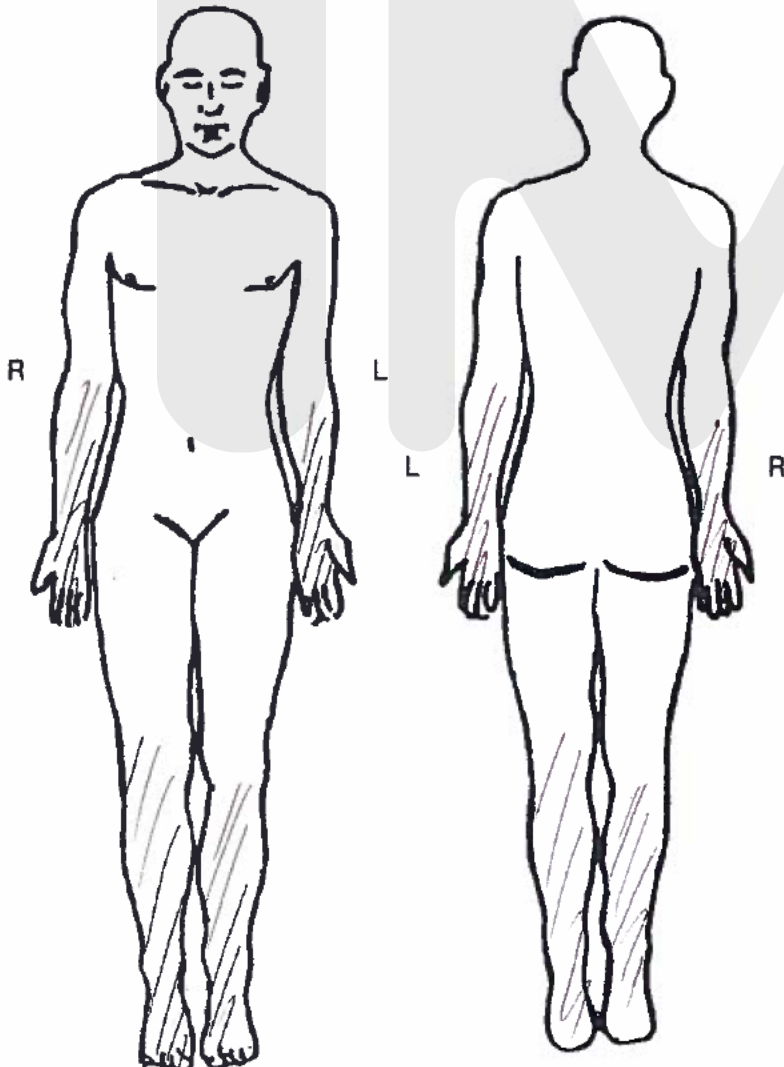
DESCRIPTION AS TO WHERE REMAINS FOUND AND CONTACT MATERIAL TO BODY:

HANGING BY LIGATURE (BELT) AROUND NECK, FEET TWITCHING FLOOR.

SCENE TEMPERATURE REGULATED? YES [] NO [X] IF YES, THERMOSTAT SET AT _____ DEGREES F.

LIVOR MORTIS: TIME OBSERVED 1128

RIGOR MORTIS: TIME OBSERVED 1125



NECK FLEXION.
 ANTERIOR 3
 POSTERIOR 3
 RT LATERAL 3
 LT LATERAL 3
 JAW 3
 SHOULDER 3
 ELBOW 3
 WRIST 3
 HIP 3
 KNEE 3
 ANKLE 3

SCALE
 0 ABSENT/NEGATIVE
 1 .
 2 .
 3 .
 4 EXTREME DEGREE

USE SCALE TO DESCRIBE INTENSITY OF RIGOR MORTIS.

SHADE DIAGRAMS TO ILLUSTRATE THE LOCATION OF LIVOR MORTIS.

DESCRIBE INTENSITY OF COLORATION AND WHETHER LIVOR MORTIS IS PERMANENT OR BLANCHES UNDER PRESSURE.

[REDACTED]
 CORONER'S INVESTIGATOR

REVIEWED BY: [Signature]

<h1>3A</h1>	CASE # 2017- DECEDENT'S NAME: BENNINGTON, CHESTER CHARL DOD: 7/20/2017 INCOMING MODE: <i>Survival</i>
-------------	--

Drug Name	Rx Number	Date of Issue	Number Issued	Number Remaining	Form	Dosage	Rx Directions	Physician	Pharmacy Phone/ Comments
ZOLPIDEM	0548007115	6/29/2017	30	1	TABLET	10MG	1 TAB AT BEDTIME		PRESCRIBED TO TALINDA BENNINGTON. TABLET BROKEN IN HALF

Paraphernalia Description	Investigator:
	Date: 7/20/2017